

An Attempted Homicidal Cut Throat Injury: A Case Study

*Mukesh Kumar Sah¹, Madhu Thakur²



¹Lecturer, Department of ENT-Head and Neck Surgery, ²Internship trainee, Department of ENT-Head and Neck Surgery, National Medical College, Birgunj, Parsa, Nepal.

*Corresponding Author: Dr. Mukesh Kumar Sah; Email: mukace.shaw@gmail.com

ABSTRACT

Homicidal cut throat is an injury over the front of neck by sharp instruments with an intent of murder. The neck contains vital structures (nerves, blood vessels, airway and pharyngeal conduit) in a compact fashion that may be difficult to access for physical examination or surgical exploration in a limited time. That is why these cases create panic and pose great challenges in the management. Here is a case of an attempted homicidal cut throat injury that highlights some of the challenges encountered in the management along with discussion on the evolving knowledge of the optimal management practice.

Keywords: Homicide; Neck injuries; Pharynx

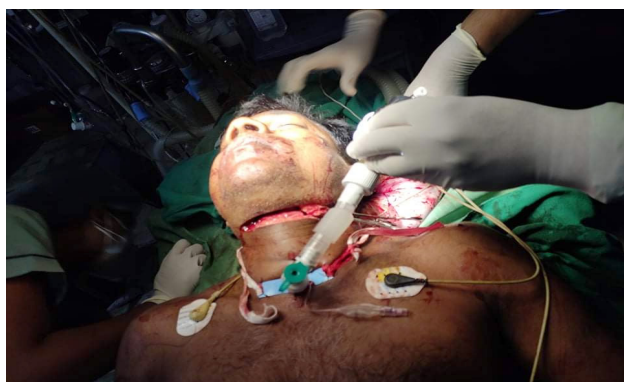Access this article Online		Article Info.
Quick Response Code	Website:	How to cite this article in Vancouver Style?
  View PDF	www.jkahs.org.np	Sah M, Thakur M. An Attempted Homicidal Cut Throat Injury. Journal of Karnali Academy of Health Sciences 2020;3(2): 147-151
	DOI: https://doi.org/10.3126/jkahs.v3i2.30728	Received : 2 July 2020 Accepted : 10 August 2020 Published Online : 11 August 2020 Conflict of Interest : None Source of Support : None

INTRODUCTION

Homicidal cut throat by definition are injuries over the front of neck by sharp instruments with an intent to kill.¹ The common causes for homicidal cut throat injuries are familial and property disputes, political conflicts and sex related crimes. Anterior and lateral neck are most exposed to trauma and most homicidal neck wounds are encountered in these regions. The neck contains vital structures including major blood vessels and airway in a compact fashion that may be difficult to access for physical examination or surgical exploration; posing a great challenge in the management.² Patients usually present with acute bleeding due to injury to major vessels, airway insufficiency, and aspiration, so prompt intervention is mandated. Primary survey, resuscitation and stabilization of the patient is followed by identification of specific injuries, definite control of bleeding vessels and operative repair. At a center having limited experience, the strategy of management becomes very important.

CASE REPORT

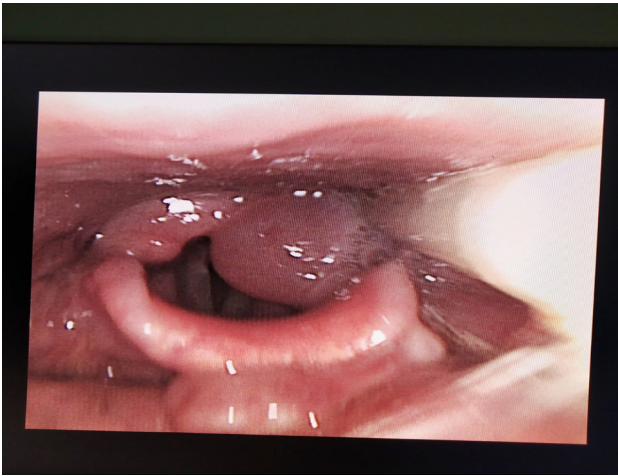A 48 year old injured male was brought to the emergency with an attempted homicidal anterior neck wound. Duration of injury was unknown and the victim was unconscious with Glasgow coma scale (GCS) score eight only. Airway was cleared by suctioning and oxygen supplementation was provided via mask over the open pharynx. Cervical spine injury was not suspected, hence we did not apply neck collar that might have compromised our working field. A 10 cm horizontal sharp wound extending across the hyoid injuring the anterior border of the sternocleidomastoid muscle bilaterally was present as shown in picture 1.



Picture 1: Intraoperative picture

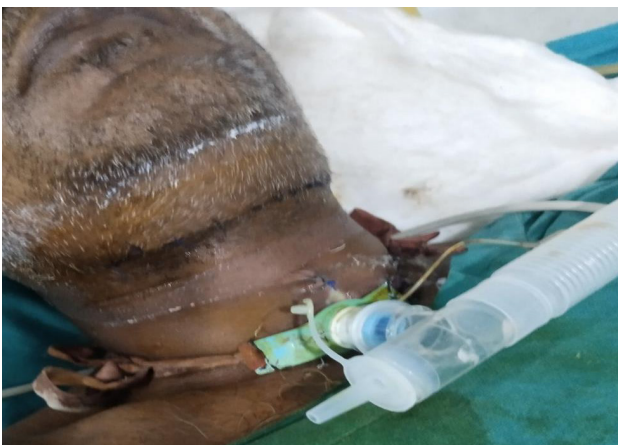Anterior belly of digastric muscle was found cut-separated bilaterally. Left posterior belly of digastric and stylohyoid were also lacerated. Active pulsatile bleeding from multiple sites were detected on arrival at the emergency. On the both sides, the submandibular salivary gland was found cut and bleeding. Anterior pharyngeal wall was open with laceration about five centimeters. In the pharynx, there was collection of clotted blood, fresh blood, saliva and mud which was wiped out and suctioned. Patient was in shock with no recordable blood pressure. Large-bore intravenous canulation and fluid resuscitation was started. Blood was sent for hemoglobin, hematocrit, blood group and cross matching. Visible actively bleeding vessels were clamped with artery forceps. A tracheostomy was performed under local anesthesia because the integrity of the airway was clearly compromised. Wound was irrigated with saline to wash out all the clots, soil and foreign bodies. Bleeding vessels were identified, clamped and tied. Wound was further examined to detect extent of injuries. On examination, tongue base was partly avulsed away from hyoid. Bilateral anterior jugular vein, left facial vein and artery and left lingual artery that were clamped in the emergency room were tied and secured at both ends. Bilateral carotid and internal jugular vessels were intact. No identifiable nerves were damaged. Laryngeal framework appeared intact. Tongue base and pharyngeal mucosa was repaired with 3-0 vicryl continuous suture after inserting the 18 F nasogastric (NG) tube through the nostril. All the injured muscles were also repaired. Subcutaneous tissue and skin were sutured in separate layers after placement of drain. Patient was moved to intensive care unit (ICU) for post-operative care where he was put on ventilator for a day. On the first postoperative day (POD), oxygen was provided at the rate of 5liter/min via Ayer's T-piece after weaning from the ventilator. Patient maintained a saturation of 90 to 100 percent. Patient was on intravenous (IV) fluid only for 24 hours until full regain of consciousness; thereafter liquid feed was started through NG tube. Intravenous antibiotics were continued till hospital stay. Flexible nasopharyngolaryngoscopy (NPL) was performed on the 7th POD that showed arytenoid edema and redundant tissue at tongue base at the site of repair

but mucosal healing at pharyngeal wound was good as shown in picture 2.



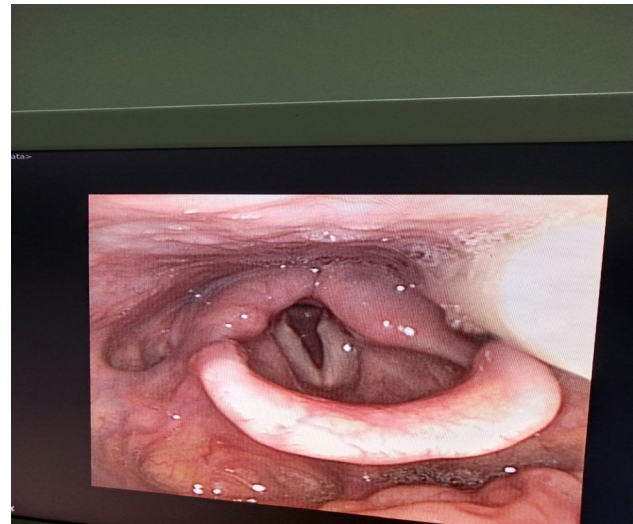
Picture 2: 7th postoperative day showing arytenoid edema and redundant tissue at tongue base at the site of repair

On 10th POD, skin wound was well healed as shown in picture 3; but when skin sutures were removed, patient developed throat pain and excessive oral secretion.



Picture 3: 10th postoperative day showing healthy skin wound

Mucosal wound dehiscence was suspected in view of neck extension during suture removal and plan for starting oral feeding and removal of NG tube was postponed for a week. Imaging and review NPL were planned. Computed tomographic scan (CT- scan) and ultra-sonogram (USG) were reassuring with no collection in the tissue plain. NPL showed no injury and improvement of arytenoid edema as shown in picture 4.



Picture 4: 10th postoperative day- edema resolved

Same conservative treatment was continued for a week. After this, oral feeding was started with clear fluids which was well tolerated. Removal of NG tube and tracheostomy tube decanulation was done over next 3 days. Patient was discharged after 3 weeks of postoperative hospital course who recovered completely, as seen in the follow up evaluation at one month.

DISCUSSION

Neck injuries are relatively uncommon in our emergency, but when present, bring about a challenge because of confinement of multiple vital structures in the small unprotected area.² Roon and Christensen have described a clinic-anatomical division of neck injuries into the three zones. Upper or zone III- above the angle of mandible, middle or zone II- from cricoid to the angle of mandible and lower or zone I- below cricoid to thoracic inlet.³ Our patient had a zone-II injury; the commonest (60-75%) site of neck injuries. Only few patients of neck injuries caused by homicidal cut throat gets saved. Injuries to vital structures: nerves, vessels, airway, esophagus and pharynx are the cause of death.⁴ Advanced Trauma Life Support (ATLS) guidelines should be followed with promptness in securing an airway, optimum oxygenation and ventilation and adequacy of the blood circulation. In the cases of cut throat injuries where there is uncertainty about the extent of injury and evaluation of the endolarynx and trachea cannot be carried out; imaging is warranted and computed

tomography remains the modality of choice.⁵ But delay in securing a definitive airway while waiting for radiologic studies is not justified. A tracheostomy, apart from assuring a patent airway, facilitates proximal injuries repair especially pharynx and larynx.^{6,7} We avoided imaging procedure and went for emergency tracheostomy under local anesthesia to maintain the airway which was used for the administration of general anesthesia. Injury to the cervical spine is rare in cut throat wounds and preventive cervical collars application is not recommended as this may obscure examination of the neck.^{6,8} Clinical findings in penetrating neck injury (PNI) are classified as “hard” or “soft” signs.^{8,9} Hard signs indicate major injury to blood vessel or aero-digestive tract. These include active bleeding, unstable hemodynamics, enlarging or pulsating hematoma, pulse deficit, central neurological compromise, non-responding shock, huge subcutaneous emphysema and airway compromise. Soft signs are: minor oozing, small stable hematoma, minimal hemoptysis, dysphonia, small emphysema and dysphagia. Patients with only soft signs undergo further investigations to decide for the surgical intervention while those with hard signs are immediately shifted for the surgical exploration. After primary survey, we moved to the operation theatre without considering for the investigations. During initial survey we had clamped all accessible bleeding vessels. This simple added effort in the emergency saved time and effort during subsequent exploration. It yielded benefit in terms of prevention of blood loss and possible aspiration while tracheostomy was being performed. The patient’s postoperative nutrition is best managed with Ryle’s tube (NG tube) feeding after pharyngeal wound repair, as it is the cheapest, easiest and the most effective route.¹⁰ Pharyngeal lacerations should ideally be repaired in multiple layers with continuous suturing with absorbable suture for mucosal layer. Endoscopic evaluation and imaging when in doubt for pharyngeal wound healing confirmation is needed before starting oral feeding to avoid the risk of pharyngocutaneous fistula development. Postoperative handling is very important, failure to which may wash out all the intraoperative excellence. Tracheostomy decanulation is the last procedure to

be performed after the neck wound health is ensured.

CONCLUSION

Cut throat injuries and associated morbidities are increasing. The timely and standard recommended guidelines based management is an essential key for a successful outcome in the cases of cut throat. Imaging that may consume golden minutes can be postponed in cases with compromised airway and circulation. Instead prompt definite airway and early exploration should be encouraged. Tracheostomy under local anesthesia in cut throat wound is an appropriate choice especially with exposed pharynx that not only ensure the patent airway but also facilitates proximal exploration and repair. Early control of bleeding from arteries is vital. Early and layer wise repair of pharyngeal wall with delayed institution of oral feed ends in good result and minimal risk of infection and fistula formation.

Authors’ Contributions: Mukesh Kumar Sah designed the case report. Data collection, literature search, writing of the report, and final decision to publish the case was carried out jointly with Madhu Thakur.

Acknowledgments: We are grateful to our patient for the permission of the case publication.

REFERENCES

1. Darlong LM, Shunyu NB, Das R, Mallik S. Cut throat zone II neck injury and advantage of a feeding jejunostomy. *J Emerg Trauma Shock*. 2009;2(3):213-215. <https://doi:10.4103/0974-2700.55353>
2. Demetriades D, Asensio JA, Velmahos G, Thal E. Complex problems in penetrating neck trauma. *Surg Clin North Am*. 1996;76(4):661-683. [https://doi:10.1016/s0039-6109\(05\)70475-8b](https://doi:10.1016/s0039-6109(05)70475-8b)
3. Roon AJ, Christensen N. Evaluation and treatment of penetrating cervical injuries. *J Trauma*. 1979;19(6):391-397. <https://doi:10.1097/00005373-197906000-00001>

4. Grewal H, Rao PM, Mukerji S, Ivatury RR. Management of penetrating laryngotracheal injuries. *Head Neck*. 1995;17(6):494-502. <https://doi:10.1002/hed.2880170607>
5. Offiah C, Hall E. Imaging assessment of penetrating injury of the neck and face. *Insights Imaging*. 2012;3(5):419-431. <https://doi:10.1007/s13244-012-0191-y>
6. Brywczyński JJ, Barrett TW, Lyon JA, Cotton BA. Management of penetrating neck injury in the emergency department: a structured literature review. *Emerg Med J*. 2008;25(11):711-715. <https://doi:10.1136/emj.2008.058792>
7. Shearer VE, Giesecke AH. Airway management for patients with penetrating neck trauma: a retrospective study. *Anesth Analg*. 1993;77(6):1135-1138. <https://doi:10.1213/00000539-199312000-00009>
8. Burgess CA, Dale OT, Almeyda R, Corbridge RJ. An evidence based review of the assessment and management of penetrating neck trauma. *Clin Otolaryngol Off J ENT-UK; Off J Netherlands Soc Oto-Rhino-Laryngology Cerv-fac Surg*. 2012;37(1):44-52. <https://doi:10.1111/j.1749-4486.2011.02422.x>
9. Sperry JL, Moore EE, Coimbra R, et al. Western Trauma Association critical decisions in trauma: penetrating neck trauma. *J Trauma Acute Care Surg*. 2013;75(6):936-940. <https://doi:10.1097/TA.0b013e31829e20e3>
10. Chakraborty D, Das C, Verma AK, Hansda R. Cut Throat Injury: Our Experience in Rural Set-Up. *Indian J Otolaryngol Head Neck Surg*. 2017;69(1):35-41. <https://doi:10.1007/s12070-016-1033-x>