

# Morphometric Analysis of Hard Palate on Nepalese Population

\*Sushma Khatiwada,<sup>1</sup> Rajib Chaulagain,<sup>2</sup> Gulam Anwer Khan,<sup>3</sup> Srijana Mishra Sapkota,<sup>4</sup> Budhi Nath Adhikari Sudhin<sup>5</sup>

<sup>1</sup>Lecturer, Department of Anatomy, Chitwan Medical College, Bharatpur-10, Chitwan, Nepal

<sup>2</sup>Lecturer, Department of Oral Pathology, Chitwan Medical College, Bharatpur-10, Chitwan, Nepal

<sup>3</sup> Associate Professor, Department of Anatomy, Chitwan Medical College, Bharatpur-10, Nepal

<sup>4</sup> Lecturer, Department of Prosthodontics, Chitwan Medical College, Bharatpur-10, Nepal

<sup>5</sup> Registrar, B P Koirala Memorial Cancer Hospital, Bharatpur-7, Chitwan, Nepal

\* **Corresponding Author:** Dr Sushma Khatiwada; Email: [khatiwadasushz@gmail.com](mailto:khatiwadasushz@gmail.com)

## ABSTRACT



**Background:** The hard palate is an important part of the human skull located between the nasal and the oral cavity. Hard palate plays an important role in the production of speech. The present study aimed to measure the morphometry of the hard palate and explore the existence of gender related differences since limited similar studies has been carried out.

**Methods:** This study was conducted to assess the palatal dimensions in a sample of Nepalese individuals aged 18–25 years with class I molar occlusion. The data collection was done from January 2020 to March 2020. The length, breadth and height of the hard palate were measured and palatine indices as well as palatal height indices were calculated. Differences between males and females were tested for the palatal variables.

**Results:** Mean palatal length, breadth and width were  $41.58 \pm 3.48$  mm,  $40.63 \pm 3.76$  mm, and  $14.90 \pm 2.04$  mm respectively. We found significant gender difference in palatal morphometry in the cast we analyzed. The palatine index of majority of dental cast was of brachystaphyline type (84.85%). Calculation of the palatine height index demonstrated predominance of orthostaphyline type (71.21%) of dental casts.

**Conclusion:** The present study provides important palatal morphological data of the Nepalese population which can be helpful for orthodontic treatment as well as for anthropological studies, greater palatine nerve blocks and surgical procedures on the hard palate.

**Keywords:** Hard palate, Morphometric analysis, Palatal dimension, Palatine height index, Palatine index.

Access this article Online		ArticleInfo.
Quick Response Code	How to cite this article in Vancouver Style?	
	Khatiwada S, Chaulagain R, Khan GA, Mishra Sapkota S, Adhikari Sudhin BN. Morphometric Analysis of Hard Palate on Nepalese Population. Journal of Karnali Academy of Health Sciences. 2020; 3(3)	
	Received: 21 September 2020	Accepted: 19 November 2020      Published Online: 20 November 2020
	Source of Support: Self	Conflict of Interest: None
<p><b>Copyright:</b> © 2020 by author(s) in which author(s) are the sole owners of the copyright of the content published.</p> <p><b>Licensing:</b> The Journal follow open access publishing policy, and available freely in the <a href="#">website of the Journal</a> and is distributed under the terms of the <a href="#">Creative Commons Attribution International License 4.0</a> under the CC-BY 4.0  license, and the author(s) retain the ownership of the copyrights and publishing rights without restrictions for their content, and allow others to copy, use, print, share, modify, and distribute the content of the article even in commercial purpose as long as the original authors and the journal are properly cited.</p> <p><b>Disclaimer:</b> The statements, opinions and data contained in this publication are solely those of the individual author(s) and contributor(s). Neither the publisher nor editor and reviewers are responsible for errors in the contents nor any consequences arising from the use of information contained in it. The Journal as well as publisher remain neutral with regards to any jurisdictional claims in any published articles, its contents and the institutional affiliations of the authors.</p>		

## INTRODUCTION

The bony palate is formed by the palatine processes of the maxillae anteriorly and the horizontal plates of the palatine bones posteriorly which are linked by a cruciform system of sutures.<sup>1</sup> Hard palate starts to develop from the palatine shelves from both side and fuse in the midline around sixth week of intrauterine life.<sup>2</sup>

The palate plays a major role in the passive articulation of speech.<sup>3</sup> Accurate assessment of the hard palate has many clinical applications, notably in the fields of forensic anthropology, orthodontic surgeries, palatal implants, repair of cleft palate and treatment of obstructive sleep apnea syndrome.<sup>4-6</sup>

Palatal measurement varies among individuals according to pattern of craniofacial growth and by several genetic and environmental factors. Prolonged mouth breathers and individuals with enlarged tonsils or nasal allergies have altered palatal dimensions as well.<sup>7</sup> Gender differences between individual palatal measurements have been documented by several investigators,<sup>7-10</sup> while some could not find significant differences.<sup>11,12</sup>

Studies on the morphometry of the palate has been scarcely carried out in Nepal and clinician have to largely depend on western data or data from our neighboring countries for normal values which may not be always accurate.<sup>13,14</sup> This study aimed at investigating the morphology of the hard palate in Nepalese population for generating normative values regarding its length, width and depth and to identify any gender differences between them.

## MATERIALS AND METHODS

This was a descriptive observational study approved by the Institutional Review Committee of Chitwan Medical College (CMC-IRC/076/077-120). The study was carried out from January 2020 to March 2020 at Prosthodontics lab of Chitwan Medical College. Sample was estimated based on simple random sampling technique with two means by using the following formula:

$$n = 2(Z_{\alpha} + Z_{1-\beta})^2 \sigma^2 / \Delta^2$$

The following values were used for the calculation -

Difference between two means (length) in a similar study (Mustafa et al<sup>10</sup>):  $\Delta = 43 - 39 = 4$

Population standard deviation of two groups combined:  $\sigma = 5$

Confidence level: 95%  $\rightarrow Z_{\alpha} = 1.96$

Power of test: 90%  $\rightarrow Z_{1-\beta} = 1.28$

Thus, a total sample size of 66 was obtained. Sixty six cast from patients and students were involved in the study. Cases with the following features were included in our study: Fully dentate with the exception of third molars, Class I molar occlusion, not having significant respiratory and allergy history and no previous orthodontic treatment or orthognathic surgery. Dental casts with severe malocclusion or crowding anteriors were excluded from our study.

Data collection was done by the principal investigator and a co-investigator together. Principal investigator was involved in taking the measurements and the co-author noted the measurements and clicked the photographs. A 150 mm digital vernier caliper (accurate up to 0.01 mm, product of China) was used to perform all the measurements. Each of the cast was given a serial number by

which the details of the subjects were easily found out from the project files whenever needed. Detailed procedure of measurement is in the text below.

**Length of the palate** - The length of the palate was measured as a distance from the *orale* (point at the anterior end between the two maxillary central incisors) to the midpoint of the line joining the posterior surface of second molars.



Figure 1: Measurement of Palatal length

**Width of palate** - The width was measured as the distance between the inner borders of the second molars.




Figure 2: Measurement of Palatal width

**Height of palate** - Stainless steel wire corresponding with the transverse length at the level of canine, 1<sup>st</sup> premolar and 1<sup>st</sup> molar were cut and secured at the edges with wax. The height was measured at the highest point of the palatal vault at first molar. The final height of the palate was calculated after deducting the diameter of the stainless steel wire (0.5 mm) from the reading on the caliper.

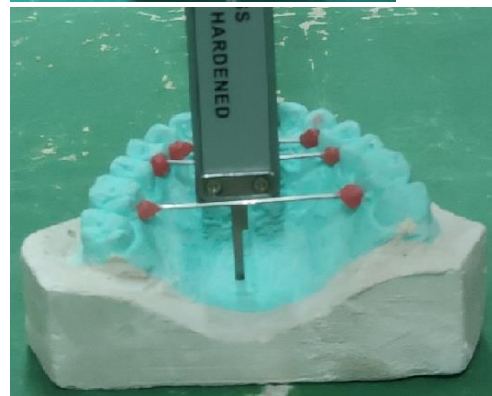


Figure 3 and 4: Measurement of Palatal height  
Palatine index: The Palatine index (PI) was calculated by the formula given by Hassanali and Mwaniki.<sup>15</sup>

$PI = \text{Palatine width} / \text{Palatine length} \times 100$ .

The PI is the ratio of the palatine width to the palatine length expressed as a percentage.

1) PI if less than 79, the palate is narrow (Leptostaphyline)

2) PI if 80-84.9, the hard palate is intermediate (Mesostaphyline)

3) PI if 85 or more, the hard palate is broad (Brachystaphyline)

Palatine height index: was calculated by using the formula:

$\text{Palatine height} / \text{Palatine breadth} \times 100$

According to the palatine height index there are 3 types of hard palate.

Chamestaphyline (low) - palatine height index < 27.9%.

Orthostaphyline (intermediate) - palatine height index between 28.0 - 39.9%.

Hypsistaphyline (deep) - palatine height index > 40%.

### Data Analysis

All the data were numerically coded in excel and then transferred to Statistical Analysis System (SAS) university edition software.

The mean, standard deviation and range was calculated and described to see patterns and behavior of the variables were measured. For inferential analysis, student t-test was applied to determine the difference between the means of male and female with respect to length, width and height respectively.

## RESULTS

This study included a total of 27 male and 39 female maxillary casts. Table 1 depicts the mean palatal dimensions (length, width, and height) along with standard deviation for each gender in the study sample. Those parameters were compared between males and females using students' t-test which was found to be statistically significant ( $p < 0.05$ ).

Table 1: Mean palatal arch dimensions

Variable	Male Mean $\pm$ SD (mm)	Female Mean $\pm$ SD (mm)	Total Mean $\pm$ SD (mm)	p value
Length	39.49 $\pm$ 3.10	43.02 $\pm$ 2.98	41.58 $\pm$ 3.48	<0.0001
Width	42.52 $\pm$ 3.72	39.32 $\pm$ 3.28	40.63 $\pm$ 3.76	<0.0001
Height	16.70 $\pm$ 1.26	13.65 $\pm$ 1.50	14.90 $\pm$ 2.04	<0.0001

Palatine index and palatine height index of our study population are shown in Figure 5 and 6 respectively.

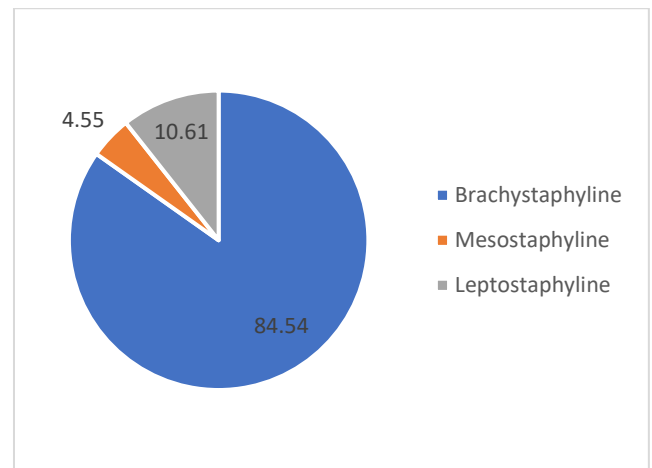


Figure 5: Distribution of palatine index

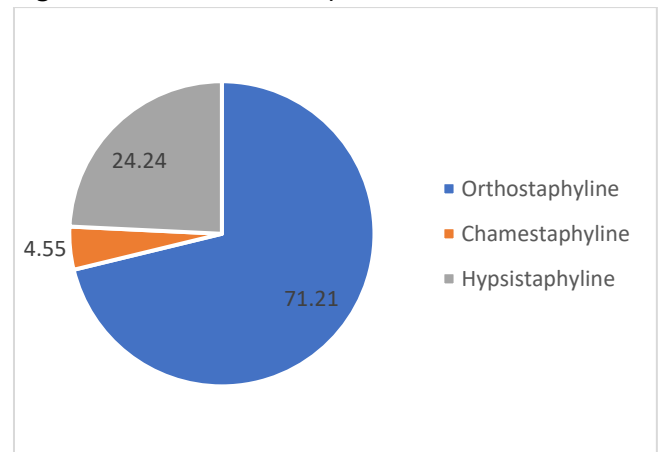


Figure 6: Distribution of palatine height index

## DISCUSSION

Apart from gender, race and ethnicity of the study population, measurement of the palatal dimensions varies according to the method and landmarks chosen. This study is one of the few morphometric analysis study to investigate the hard palate in Nepalese population with class 1 occlusion.

The mean palatal length in our study was found out to be  $41.58 \pm 3.48$  mm. Mustafa et al in 150 dental casts of adult males and females found it to be  $43.91 \pm 2.65$  and  $39.53 \pm 2.73$  mm respectively and reported that all the measurements had significant gender differences.<sup>10</sup>

Unlike our study, Al-Zubair et al took a line connecting the 1<sup>st</sup> molars as the posterior limit of palatine length and found its mean as  $30.05 \pm 2.03$  mm. Interestingly, like our study, they also found that females had longer palates as compared to males.<sup>7</sup>

Nahidh et al by taking a point intersecting the mid-sagittal plane with a line passing over the widest point of the incisive papilla as the anterior limit and a line joining most distal point of 1<sup>st</sup> molars as the posterior limit, found the mean palatal length as  $28.97 \pm 1.55$  mm with no gender differences.<sup>16</sup> Ahmed et al calculated the mean value of palatal length for different types of palates in both gender and found no significant differences for any type of palate.<sup>17</sup>

Unlike the previous studies on dental casts, various other studies on palatal morphology have used dry human skulls. Sarilita et al measured the palatal length from the *orale* to the posterior nasal spine of dried skull and found the mean as  $52.2 \pm 3.2$  mm (range 42.7 - 59.6 mm).<sup>18</sup> Other studies by Klosek et al, Shalaby et al, Jaffar et al, Dave et al and Jotania et al have found the mean palatal length as  $51.4 \pm 5.8$  mm,  $51.65 \pm 4.7$  mm,  $5.082 \pm 0.359$  cm (range 4.33 - 5.7 cm),  $43.54 \pm 0.28$  mm and 49.74 mm respectively.<sup>11,12,19-21</sup>

Tomaszewska et al in their systematic review and metaanalysis included studies involving dry skulls as well as CT images and found palatal length in the range of 47.0 to 52.4 mm.<sup>22</sup> All of these variations in palatal length may be due to number of sample size taken, geographical or ethnic differences. We found the mean palatal width in our population to be  $40.63 \pm 3.76$  mm. Mustafa et

al in a similarly performed study found it to be  $45.05 \pm 2.47$  mm and  $40.23 \pm 2.01$  mm in 66 males and 84 females.<sup>10</sup> Similarly, Annapurna et al found average palatal width as  $3.82 \pm 0.32$  cm in normal palate of 60 patients attending a government hospital in India.<sup>23</sup>

Width of the palate at the level of 1<sup>st</sup> permanent molars was found to be  $41.7 \pm 2.8$  mm by Al-Zubair et al,  $35.06 \pm 3.51$  mm by Nahidh et al and  $37.09 \pm 3.3$  mm by Alshahrani et al.<sup>7,16,24</sup> Ahmed et al found significant gender differences in palatal width at the level of 1<sup>st</sup> molar for all but leptoprosopic facial form.<sup>17</sup> Sexual differences in width was also noted by Al-Zubair et al, Mustafa et al and Ahmed et al.<sup>7,10,17</sup>

Sarilita et al<sup>18</sup> measured the mean palatal width in human skull and found its mean as  $37.97 \pm 3.32$  mm (range 30.1 - 47.9 mm) while Klosek et al, Hassanali et al, Jaffar et al, Dave et al and Jotania et al found it as  $31.1 \pm 5.2$  mm,  $4.02 \pm 0.30$  cm,  $3.929 \pm 0.341$  cm,  $33.83 \pm 0.2$  mm and 37.75 mm respectively.<sup>11,15,19-21</sup> Tomaszewska et al found mean palatal width as  $46.9 \pm 3.3$  mm in their metaanalysis of European studies involving 1350 skulls.<sup>22</sup> Klosek et al noted no gender difference in palatal width as well as height.<sup>11</sup>

Palatal height was the dimension least studied amongst all the three measurements. We found it as  $14.90 \pm 2.05$  mm in our study. Annapurna et al measured it at different planes and found deepest value of  $1.77 \pm 0.15$  cm at the level of 2<sup>nd</sup> permanent premolars.<sup>23</sup> Alshahrani et al measured the mean palatal height of the casts with class I malocclusion as  $20.76 \pm 3.1$  mm.<sup>24</sup> Alkadhi et al noted mean palatal height in males and females as  $20.90 \pm$



2.08 and  $20.54 \pm 2.09$  mm respectively.<sup>25</sup> Nahidh et al measured the mean palatal height in dental casts with type 1 malocclusion and found it to be  $14.9 \pm 1.78$  mm.<sup>16</sup> Zarringhalam et al combined different methods for palatometry including direct observation, cephalometry and dental cast analysis and found no gender differences in palatal height.<sup>26</sup> Using dried human skulls, Sarilita et al<sup>18</sup> found the mean height as  $11.54 \pm 2.4$  mm (range 6 – 17 mm) while Klosek et al, Hassanali et al, Dave et al and Tomaszewska et al found it as  $17.7 \pm 4.2$  mm,  $1.22 \pm 0.16$  cm,  $9.87 \pm 0.23$  mm and  $13.1 \pm 2.7$  mm respectively.<sup>11,15,20,22</sup>

Berwig et al had given a wide range of reference data on palatal dimensions of different countries in their metaanalysis of 18 studies from across the globe in 2018.<sup>27</sup> They found five studies with significant difference between males and females palatal length, while four others had no differences. In two studies, they noted that males had longer palates, while two studies showed no gender differences. A Mongolian study showed that females had longer palates as compared to males. They noticed no gender difference in depth in the single study that analyzed the depth of the palate.

Anil et al found statistically significant gender differences in palatal length and breadth but not height in their study of 86 dried unsexed Indian skulls.<sup>8</sup> Al-Zubair et al noticed that male seemed to have greater (mean value  $\pm$  SD) palatal width and depth (width  $41.7 \pm 2.8$  mm and depth  $21.2 \pm 1.5$  mm) as compared to females (width  $39.1 \pm 2.3$  mm and depth  $20.7 \pm 1.4$  mm).<sup>7</sup>

Palatine index calculation utilizes length and width of the palate which in turn are derived from various studies utilizing various landmarks and references. Most of the data on palatine index in the literature are derived from studies on dry skull and thus, comparison would not make much sense. Classification of types, however, may be used for descriptive purposes. Palatine index of our study along with others are depicted below in Table 2. The knowledge of palatine index is important because high and narrow palate has been reportedly associated with many syndromes such as Apert syndrome, Turner's syndrome, Marfan syndrome and Franceschetti-Teacher-Collins syndrome.<sup>8</sup> Palatal height index of our study as well as other similar studies is shown in Table 3.

Table 2: Palatine index (PI)

Study	Mean Palatine Index ( $\pm$ SD)	Narrow PI (<79.9) %	Intermediate PI (80 – 84.9) %	Wide PI (>85) %
Hassanali et al <sup>15</sup>	$82.01 \pm 7.84$	43.2	23.7	33.1
D'Souza et al <sup>4</sup>	-	37.5	22.5	40
Dave et al <sup>20</sup>	$77.97 \pm 7.02$	63	24	13
Jotania et al <sup>21</sup>	-	70	15	15
Ortug et al <sup>28</sup> (palatine index)	$83.37 \pm 10.90$	38.3	24.4	37.5
Present study	$98.73 \pm 14.72$	10.61	4.55	84.85

Table 3: Palatine height index

Study	Mean Palatine Height Index ( $\pm$ SD)	Chamestaphyline < 27.9	Orthostaphyline 28 - 39.9	Hypsistaphyline > 40
Hassanali et al <sup>15</sup>	30.30 $\pm$ 6.30	40.0	56.67	3.33
D'Souza et al <sup>4</sup>	-	87.5	12.5	-
Dave et al <sup>20</sup>	29.23 $\pm$ 2.54	42	54	4
Sarilita et al <sup>18</sup>	30.5 $\pm$ 6.43	32	59	10
Shalaby et al <sup>12</sup>	-	36	56	8
Anil et al <sup>8</sup>	46.03 $\pm$ 1.33 (Male), 34.66 $\pm$ 2.05 (Female)	40.69	44.18	15.11
Annapurna et al <sup>23</sup>	41.98 $\pm$ 9.82	-	-	-
Present study	36.82 $\pm$ 5.03	4.55	71.21	24.2

Anil et al and Shalaby et al noted that palatal height index had significant gender differences. <sup>8,12</sup> Females have smaller bony ridge and alveolar process; average weakness of musculature combined with earlier growth of arch as compared to males may explain lower palatal dimensions in females, especially in the transverse and vertical dimensions.

#### Limitation of the study

This was a hospital based study having adults of narrow age group and with Class I molar occlusion only. This may have introduced some bias in the study.

#### REFERENCE

1. Standring S, 'Head and Neck' in Gray's Anatomy: The Anatomical Basis of Clinical Practice, 41<sup>st</sup> edition, Churchill Livingstone, London, 2016:510-11.
2. Sadler TW. 'Head and Neck' in Langman's Medical Embryology, 14th edition, Wolters Kluwer, Philadelphia, 2018:301-2.

#### CONCLUSION

Anatomical and morphometric knowledge of the hard palate is advantageous in various fields of medical science. The current study provides important morphometric data of Nepalese hard palate which may be valuable to provide anthropological references and help clinicians working in the vicinity of the palate.

**Acknowledgment:** The authors would like to thank Dr Smriti Narayan Thakur, Department of Prosthodontics, Chitwan Medical College; and Mr Naresh Khatiwada for his help in statistical analysis of the raw data.

3. Varalakshmi KL, Sangeeta M, Shilpa N, Arunashri A. An osteological study of morphometry of hard palate and its importance. International Journal of Research in Medical Sciences.2015; 3(9):2210-3. <https://doi.org/10.18203/2320-6012.ijrms20150603>
4. D'Souza AS, Mamatha H, Jyothi N. Morphometric analysis of hard palate in South Indian skulls. Biomed Res.2012; 23(2):173-5. [\[Link\]](#)

5. Manjunath TH, Kuppast NC, Shahina, Umesh SR, Iddalgave D. Identification of gender from dimensions of palate. *Medico-Legal Update*.2014; 14(1):132-4. [\[Link\]](#)  
<https://doi.org/10.5958/j.0974-1283.14.1.032>
6. Kulkarni V, Ramesh VR. Palatometry in South Indian skulls and its clinical implications. *Int J Anat Res*.2017; 5(1):3362-66. [\[Link\]](#)  
<https://doi.org/10.16965/ijar.2016.477>
7. Al-Zubair NM, Al-Labani MA, Al-Motareb FL. Yemeni palatal morphology. *Saudi J Health Sci*.2015; 4(2):88-91. [\[Link\]](#)  
<https://doi.org/10.4103/2278-0521.157866>
8. Anil K, Ajmani ML, Heming T. Morphological and morphometric study of hard palate in Indian population. *International Journal of Biomedical Research*.2016; 7(11):778-84. [\[Link\]](#)  
<https://doi.org/10.7439/ijbr.v7i11.3706>
9. Mankapure PK, Barpande SR, Bhavthankar JD. Evaluation of sexual dimorphism in arch depth and palatal depth in 500 young adults of Marathwada region, India. *J Forensic Dent Sci*.2017; 9:153-6. [\[Link\]](#)  
[https://doi.org/10.4103/jfo.ifds.13\\_16](https://doi.org/10.4103/jfo.ifds.13_16)
10. Mustafa AG, Allouh M, Tarawneh I, Alrbata R. Morphometric analysis of palatal rugae among Jordanians: further evidence of worldwide palatal rugae individuality. *Australian Journal of Forensic Sciences*.2013; 46(1):53-63.  
<https://doi.org/10.1080/00450618.2013.804947>
11. Klosek SK, Rungruang T. Anatomical study of the greater palatine artery and related structures of the palatal vault: considerations for palate as the subepithelial connective tissue graft donor site. *Surg Radiol Anat*.2009; 31:245-50.  
<https://doi.org/10.1007/s00276-008-0432-4>
12. Shalaby SA, Eid EM, Sarg NAS, Sewilam AMA. Morphometric analysis of hard palate in Egyptian skulls. *Benha Medical Journal*.2015; 32:59-72. [\[Link\]](#)
13. Kallianpur S, Desai A, Kasetty S, Sudheendra US, Joshi P. An anthropometric analysis of facial height, arch length, and palatal rugae in the Indian and Nepalese population. *J Forensic Dent Sci*.2011; 3:33-7.  
<https://doi.org/10.4103/0975-1475.85294>
14. Shrestha RM, Bhattarai P. Dental arch length and arch symmetry analysis of Nepalese permanent dentition. *J Nepal Dent Assoc*.2009; 10:110-4. [\[Link\]](#)
15. Hassanali J, Mwaniki D. Palatal analysis and osteology of the hard palate of the Kenyan African skulls. *Anat Rec*.1984; 209:273-80.  
<https://doi.org/10.1002/ar.1092090213>
16. Nahidh M, Al-Khawaja NFK, Ghazi A. Palatal dimensions in different occlusal relationships. *J Bagh Coll Dentistry*.2012; 24(1):116-20. [\[Link\]](#)
17. Ahmed HMA, Al-Khawaja NFK, Nahidh M. Assessment of Palatal Dimensions in a Sample of Iraqi Adults with Different Facial Forms. *Iraqi Orthod J*.2014; 10(1):8-11. [\[Link\]](#)
18. Sarilita E, Soames R. Morphology of the hard palate: a study of dry skulls and review of the literature. *Rev Arg de Anat Clin*.2015; 7(1):34-43.  
<https://doi.org/10.31051/1852.8023.v7.n1.14157>
19. Jaffar A, Hamadah H. An analysis of the position of the greater palatine foramen. *J Basic Med Sci*.2003; 3:24-32. [\[Link\]](#)
20. Dave MR, Gupta S, Vyas K, Joshi HG. A Study of Palatal Indices and Bony Prominences and Grooves in the Hard Palate of Adult Human Skulls. *NJIRM*.2013; 4(1):7-11. [\[Link\]](#)
21. Jotania B, Patel S, Patel S, Patel P, Patel S, Patel K. Morphometric analysis of hard palate. *Int J Res Med*.2013; 2(2):72-5. [\[Link\]](#)
22. Tomaszewska IM, Tomaszewski KA, Kmiotek EK, Pena IZ, Urbanik A, Nowakowski M et al. Anatomical landmarks for the localization of the greater palatine foramen – a study of 1200 head CTs, 150 dry skulls, systematic review of literature and meta-analysis. *J Anat*.2014; 225:419-35.  
<https://doi.org/10.1111/joa.12221>
23. Annapurna P, PeruriPushyami. A study on hard palate and high arched palate: a morphometric study with associated traits. *Int J Anat Res*.2019; 7(2.3):6657-62. [\[Link\]](#)  
<https://dx.doi.org/10.16965/ijar.2019.198>
24. Alshahrani I, Syed S, Dawasaz AA, Togoo RA, Addas MK, Assaf A. Developmental Association of Palatal Dimensions and Palatal Rugae



Characteristics in Angle's Classes I, II and III of Malocclusion. *Int. J. Morphol.* 2019; 37(2):744-51.

<https://doi.org/10.4067/S0717-95022019000200744>

25. Alkadhi OH, Almahfouz SF, Tokhtah HA, Binhuwaishel LA. Dental arch dimensions in Saudi adults. *International Journal of Dentistry*. 2018; 10:1-10.

<https://doi.org/10.1155/2018/2190250>

26. Zarringhalam M. Measuring palatal height in normal occlusion and malocclusions. *Front Dent*. 2004; 1(4):39-42. [\[Link\]](#)

27. Berwig LC, Marquezan M, Milanesi JM, Montenegro MM, Ardenghi TM, da Silva AMT. Do gender and age influence hard palate dimensions? A systematic review. *CoDAS*. 2018; 30(5):e20170216.

<https://doi.org/10.1590/2317-1782/20182017216>

28. Ortug A, Uzel M, Greater palatine foramen: assessment with palatal index, shape, number and gender. *Folia Morphol.* 2019; 78(2):371-7.

<https://doi.org/10.5603/FM.a2018.0088>