

Idiopathic Intracranial Hypertension (IIH) Post COVID-19 Infection: Case Report

Pradeep Bastola,¹ Polina Dahal,¹ Mandira Khadka,¹ Nand Kishor Gupta,¹ Sheeksha Bastola,² Sunil Koirala³

¹Department of Ophthalmology, Chitwan Medical College

²NAME-Institute for Medical Education, Kathmandu, Nepal

³Department of Neurology, National Academy of Medical Sciences, Kathmandu, Nepal

Corresponding Author:

Dr. Pradeep Bastola, Contact: bastola.pradeep@cmc.edu.np, drbastola15@gmail.com : +977 98560-30122



ORCID: <https://orcid.org/0000-0001-9572-2759>

ABSTRACT

Pseudotumor cerebri or benign intracranial hypertension (BIH) or idiopathic intracranial hypertension (IIH) is a clinical condition that includes headache, papilledema, increased blood pressure, and clear cerebrospinal fluid. Multiple causes have been described for this condition, including venous sinus thrombosis, the toxicity of some substances such as vitamin A, tetracyclines and oral contraceptives, and sepsis besides patients related factors like obesity and middle-aged females.

We report here a case of pseudotumor cerebri in a 28-years old lady presenting to the Department of Ophthalmology, Chitwan Medical College (CMC), Nepal with a history of COVID-19 infection two months earlier. To our knowledge, this is the first report of post-COVID-19 associated isolated Benign Intracranial Hypertension (BIH) from Nepal.

Keywords: Benign intracranial hypertension; COVID-19; headache, obesity.

Access this article Online		ArticleInfo.	
QR Code	How to cite this article in Vancouver Style?		
	Bastola P, Koirala S, Polina Dahal. Case Report Idiopathic Intracranial Hypertension (IIH) Post COVID-19 Infection: Case Report: Pseudotumor Cerebri Post COVID-19 Infection: a case report. Journal of Karnali Academy of Health Sciences. 2021; 4(3)		
	Received: 29 August 2021	Accepted: 29 December 2021	Published Online: 30 December 2021
	Source of Support: Self		Conflict of Interest: None
Scan Me			
<p>Copyright: © 2021 by the author(s) in which author(s) are the sole owners of the copyright of the content published.</p> <p>Licensing: The Journal follow open access publishing policy, and available freely in the website of the Journal and is distributed under the terms of the Creative Commons Attribution International License 4.0 under the CC-BY 4.0  license, and the author(s) retain the ownership of the copyrights and publishing rights without restrictions for their content, and allow others to copy, use, print, share, modify, and distribute the content of the article even in commercial purpose as long as the original authors and the journal are properly cited.</p> <p>Disclaimer: The statements, opinions and data contained in this publication are solely those of the individual author(s) and contributor(s). Neither the publisher nor editor and reviewers are responsible for errors in the contents nor any consequences arising from the use of information contained in it. The Journal as well as publisher remain neutral with regards to any jurisdictional claims in any published articles, its contents and the institutional affiliations of the authors</p>			

INTRODUCTION

Pseudotumor cerebri (PTC), also known by the name idiopathic intracranial hypertension (IIH), is a disorder with increased intracranial pressure (ICP) and associated headaches, papilledema, vision changes, or pulsatile tinnitus within the setting of normal imaging and cerebrospinal fluid

(CSF) studies. It mainly affects overweight women of child-bearing age,¹ however woman of all ages, men, and youngsters of both sexes may be affected.² There are multiple hypotheses about the etiology of PTC including decreased CSF absorption and/or increased CSF production.^{3,4} A positive relationship exists between the feminine

sex, elevated BMI, and risk of PTC.⁵ We report here a case of pseudotumor cerebri in a lady who has had a Covid-19 infection. To our knowledge, this is a first of a report of its kind from Nepal.

CASE REPORT

A 28-year lady from urban place of central Nepal presented to the department of Ophthalmology, Chitwan Medical College with chief complaints of persisting headache for two months duration. The headache was vague and not radiating without being associated with nausea or vomiting, the lady did not give history of focal neurological deficit or similar headaches and systemic problems or medication for a headache. There was no family history of such nature. She was not hypertensive, diabetic or with any history of chronic diseases. However, she gave a history of COVID-19 infection two months back when she started having headache. The patient also gave the history of visits to a local health facility in her area for a persistent headache post-COVID-19 infection, the local health facility referred the patient to Chitwan Medical College for investigations and management.

The lady underwent a detailed Ophthalmological examination including visual acuity testing, anterior segment, and posterior segment examination. The visual acuity in both eyes were normal. Anterior segment examination did not reveal any positive findings. In the posterior segment examination, the lady had bilateral swollen optic disc (established papilledema), color vision test was normal, visual fields were grossly normal. The lady was advised for magnetic resonance imaging (MRI) head and orbit, which revealed normal findings (Figure 1).

She was ordered for complete blood count, lipid profile, and opening cerebrospinal fluid (CSF) pressure in lumbar puncture (LP). The findings from the investigations were all normal, opening CSF pressure was <200 mm of water, CSF fluid was clear and further analysis was normal. The body mass index of the patient was thirty-one (31 kg/m²). The real time polymerase chain

reaction (RT-PCR) report for COVID-19 was negative. Systemic examination was normal.

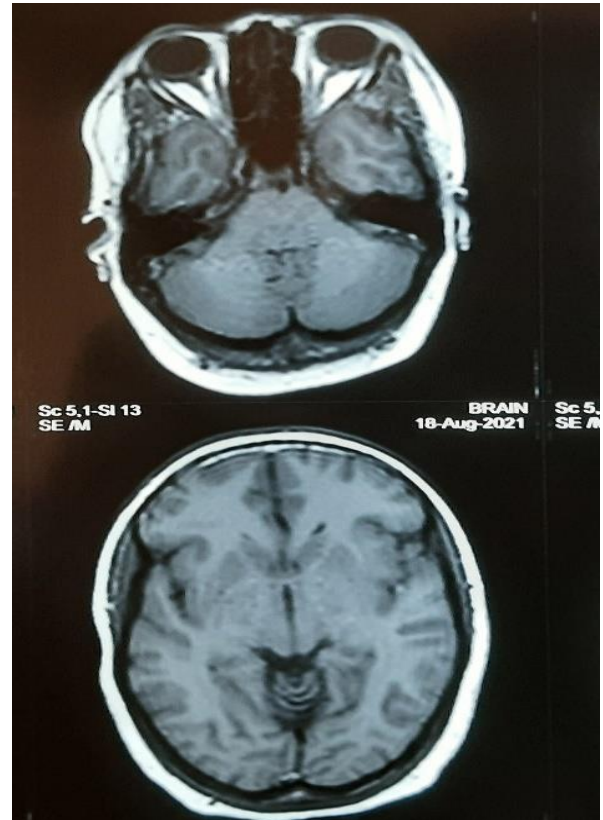


Figure 1: MRI Head and Orbit with normal findings in the study subject

The lady was thus diagnosed as a case of isolated benign intracranial hypertension post-COVID-19 infection and was consulted with the neurologist. The neurologist had a similar opinion and was in line with our diagnosis and management. The neurologist ruled out any other possible causes for headache or intracranial pathology.

The patient was then started on Tab Acetazolamide 250 mg thrice a day and advised to lose weight with an ideal target of 10% reduction. The lady was kept in regular follow-up. In the first follow up the lady responded that her headache was subsiding however the patient also complained of tingling and numbness, thorough ocular examination revealed resolving papilledema. The patient was advised to continue Tab Acetazolamide 250 mg for the next 21 days and follow up, in addition, she was also given

potassium supplements. Given the improving status clinically no new medications were added. In the last follow-up, the patient could not come to the hospital, communication was made through a telephone: there was no more headache, and she would visit a nearby eye center for her fundus check-up. The lady was advised to take the oral medication for next two months to complete the current management and follow up to our hospital.

DISCUSSION

First reported by Fabio et al. COVID-19 infection can attribute to developing benign intracranial hypertension.⁶ Idiopathic intracranial hypertension (IIH) could be a condition of increased intracranial pressure of unknown etiology, often producing papilledema and visual loss.⁷⁻⁹ IIH typically occurs in obese women within the childbearing years. The incidence of obesity has been rapidly increasing since the 1970s.¹⁰ Because obesity may be a large risk factor for IIH, the incidence of IIH conceivably could rise in parallel with this epidemic of obesity, but there are no studies to gauge this possibility.

Much of the knowledge on the incidence of IIH came from a previous epidemiology study, which demonstrated an incidence of 1.0 per 100,000 from 1976 through 1990.¹¹ The case reported here was comparable with the link of obesity with IIH and was also comparable with the findings reported by Fabio et al.⁶ Recently with the COVID-19 pandemic around there are reports of newly diagnosed IIH in subjects who had COVID-19 infection. It's been described that SARS-CoV-2 infection may be related to coagulation dysfunction, predisposing infected individuals to venous thromboembolism in several ways.¹² Pathogenic mechanisms, including endothelial dysfunction with increased levels of von Willebrand factor, systemic inflammation with Toll-like receptor activation, and a procoagulatory state via tissue factor pathway activation, are involved.¹³ Intracranial thrombosis has been implicated as a cause for intracranial hypertension

secondary to CSF outflow obstruction.¹⁴ Thus, we could speculate that venous congestion might be precipitated during a hypercoagulable state caused by SARS-CoV-2 infection.

Although our case presented with normal brain MRI, a possible hyperviscosity mechanism caused by SARS-CoV-2 would increase the blood pressure without actual epithelial duct thrombosis resulting in IIH. Thus, a low-grade inflammation determined by SARS-CoV-2 infection in conjunction with hyperviscosity and hypercoagulable state could end in intracranial hypertension in some infected individuals, and this could be the possible mechanism to develop IIH in our case being reported here.

In a recent study by Duarte-Neto et al., evidence of small vessel disease in the brain was observed in 30% of autopsies from COVID-19 patients.¹⁵ Our case in this report probably had the same mechanism as stated within the above pathophysiology with obesity, gender, and age playing important roles.

The goals of treatment with pseudotumor cerebri (PTC) include preservation of vision and reduction of symptoms (usually headache). Multiple factors should be considered when selecting both the shape of treatment and its relative urgency. The presence and degree of symptoms (i.e., headache, vision loss), the severity of vision loss, and any apparent progression are all crucial factors when deciding on the urgency of treatment. The primary step in treating any PTC patient is to spot and ameliorate conditions like anemia, causative medications, obesity, obstructive apnoea, and canal thrombosis.¹⁶ Factors in line with poor visual prognoses like high-grade papilloedema, macular edema, venous thrombosis, and systemic hypertension may support a more aggressive kind of treatment.¹⁷ Immediate aggressive management is usually advocated in cases of severe or rapidly progressive vision loss, and cases at higher risk of rapid progression (male sex, black race) without considering the severity of the disease.^{18,19} In the current case report, we had an obese lady with

normal vision and established papilledema, with persistent headache with no positive investigative reports thus, the management was conservative with regular follow up.

CONCLUSION

Idiopathic intracranial hypertension (IIH) can be one of the differential diagnoses for persistent headaches post COVID-19 infection, especially in ladies who are obese, and in reproductive age group. Persistent headache post COVID-19 infection thus requires a meticulous examination with a multidisciplinary approach to conclude a diagnosis and further management.

Acknowledgements: We would like to acknowledge the patient and patient party for being very supportive and for providing all the details regarding the progression of the disease and the reports. We would like to acknowledge

the local health center for referring the patient to Chitwan Medical College.

Strengths and limitations of the report: We believe this report would sensitize practicing medical professionals across Nepal and across border regarding idiopathic intracranial hypertension and its correlation with COVID-19 infection. In the meantime, similar reports from other parts of Nepal would give more information on COVID-19 and its association with new onset idiopathic intracranial hypertension.

Patient perspectives: The patient was compliant to the treatment provided as the intensity of headache was milder with the treatment. The patient also expressed happiness regarding the proper diagnosis and intervention provided.

REFERENCES

1. Friedman DI. The pseudotumor cerebri syndrome. *Neurol Clin.* 2014;32(2):363-96. <https://doi.org/10.1016/j.ncl.2014.01.001>
2. Phillips PH, Sheldon CA. Pediatric Pseudotumor Cerebri Syndrome. *J Neuroophthalmol.* 2017; 37:33-40. <https://doi.org/10.1097/WNO.0000000000000548>
3. McGeeney BE, Friedman DI. Pseudotumor cerebri pathophysiology. *Headache.* 2014;54:445-58. <https://doi.org/10.1111/head.12291>
4. Portelli M, Papageorgiou PN. An update on idiopathic intracranial hypertension. *Acta Neurochir (Wien).* 2017;159:491-499. <https://doi.org/10.1007/s00701-016-3050-7>
5. Gordon K. Pediatric pseudotumor cerebri: descriptive epidemiology. *Can J Neurol Sci.* 1997;24:219-21. <https://doi.org/10.1017/S031716710002182X>
6. Noro F, Cardoso FM, Marchiori E. COVID-19 and benign intracranial hypertension: A case report. *Rev Soc Bras Med Trop.* 2020;53:e20200325. <https://doi.org/10.1590/0037-8682-0325-2020>
7. Chen J, Wall M. Epidemiology and risk factors for idiopathic intracranial hypertension. *Int Ophthalmol Clin.* 2014;54:1-11. <https://doi.org/10.1097/IIO.0b013e3182aabbf11>
8. Friedman DI. Idiopathic intracranial hypertension. *Curr Pain Headache Rep.* 2007;11:62-68. <https://doi.org/10.1007/s11916-007-0024-8>
9. Wall M. Idiopathic intracranial hypertension. *Neurol Clin.* 2010;28:593-617. <https://doi.org/10.1016/j.ncl.2010.03.003>
10. Ogden, CL, Carroll, MD, Kit, BK, Flegal, KM. Prevalence of childhood and adult obesity in the United States, 2011-2012. *JAMA.* 2014;311:806-814. <https://doi.org/10.1001/jama.2014.732>

11. Kilgore KP, Lee MS, Leavitt JA, Mokri B, Hodge DO, Frank RD et al. Re-evaluating the Incidence of Idiopathic Intracranial Hypertension in an Era of Increasing Obesity. *Ophthalmology*. 2017;124:697-700. <https://doi.org/10.1016/j.ophtha.2017.01.006>
12. Gris JC, Perez-Martin A, Quéré I, Sotto A. COVID-19 associated coagulopathy: The crowning glory of thrombo-inflammation concept. *Anaesth Crit Care Pain Med*. 2020;39:381-382. <https://doi.org/10.1016/j.accpm.2020.04.013>
13. Wichmann D, Sperhake JP, Lütgehetmann M, Steurer S, Edler C, Heinemann A, Heinrich F et al. Autopsy findings and venous thromboembolism in patients with COVID-19. *Ann Intern Med* 2020;173:268-277. <https://doi.org/10.7326/L20-1206>
14. Tamer SK, Tamer U, Warey P. Infantile pseudotumor cerebri related to viral illness. *Indian J Pediatr* 1996;63:645-649. <https://doi.org/10.1007/BF02730810>
15. Dolhnikoff M, Duarte-Neto AN, de Almeida Monteiro RA, da Silva LFF, de Oliveira EP et al. Pathological evidence of pulmonary thrombotic phenomena in severe COVID-19. *J Thromb Haemost* 2020;18:1517-1519. <https://doi.org/10.1111/jth.14844>
16. Purvin VA, Trobe JD, Kosmorsky G. Neuro-ophthalmic features of cerebral venous obstruction. *Arch Neurol*. 1995;52:880-5. <https://doi.org/10.1001/archneur.1995.00540330058015>
17. Thambisetty M, Lavin PJ, Newman NJ, Biousse V. Fulminant idiopathic intracranial hypertension. *Neurology*. 2007;68:229-32. <https://doi.org/10.1212/01.wnl.0000251312.19452.ec>
18. Biousse V, Bruce BB, Newman NJ. Update on the pathophysiology and management of idiopathic intracranial hypertension. *J Neurol Neurosurg Psychiatry*. 2012;83:488-94. <https://doi.org/10.1136/jnnp-2011-302029>
19. Bateman GA, Stevens SA, Stimpson J. A mathematical model of idiopathic intracranial hypertension incorporating increased arterial inflow and variable venous outflow collapsibility. *J Neurosurg*. 2009;110:446-56. <https://doi.org/10.3171/2008.6.17609>