

# A Rare Case Report on Ileal Perforation due to Ingested Mutton Bone

Gakul Bhatta<sup>1</sup>, Balaram Malla<sup>2</sup>, Nripesh Rajbhandari<sup>3</sup>

<sup>1</sup> Lecturer, Karnali Academy of Health Sciences

<sup>2</sup> Associate Professor, Dhulikhel Hospital, Kathamndu University Hospital

<sup>3</sup> Lecturer, Dhulikhel Hospital, Kathamndu University Hospital

## Corresponding Author:

**Dr. Gakul Bhatta**

Email: [gakul.one@gmail.com](mailto:gakul.one@gmail.com)

Contact No.: +977-9851131431

## Access this article online

Quick Response Code



[View PDF](#)

Website:

[www.jkahs.org.np](http://www.jkahs.org.np)

DOI:

<http://dx.doi.org/10.3126/jkahs.v2i1.24418>

## ABSTRACT

Perforation due to foreign body is not a common cause of surgical emergency. Delay in diagnosis might lead to peritonitis and subsequently sepsis and eventually death. A case with external ileal perforation warrants a wider knowledge sharing for the benefit of medical community. Thus, it makes an important case to be reported.

**Keywords:** *Foreign Body, Perforated hollow viscus*

## INTRODUCTION

Acute abdominal perforation is one of the most common complaints in the emergency department. Most of the ingested foreign bodies are excreted via stool without causing any problem. Only about 1% of the intestinal perforation is caused by foreign body and most commonly at ileal level<sup>1</sup>. Commonly, foreign bodies' causes intestinal obstruction, perforation or fistula formation all of which can be fatal, if not timely managed. Although, not commonly anticipated, suspected foreign bodies in the gastrointestinal tract are best investigated by Computed Tomography. Intestinal perforation should be considered, diagnosed and intervened early to prevent morbidity and/or mortality. We are reporting a rare case of ileal perforation due to ingested bone

## CASE PRESENTATION

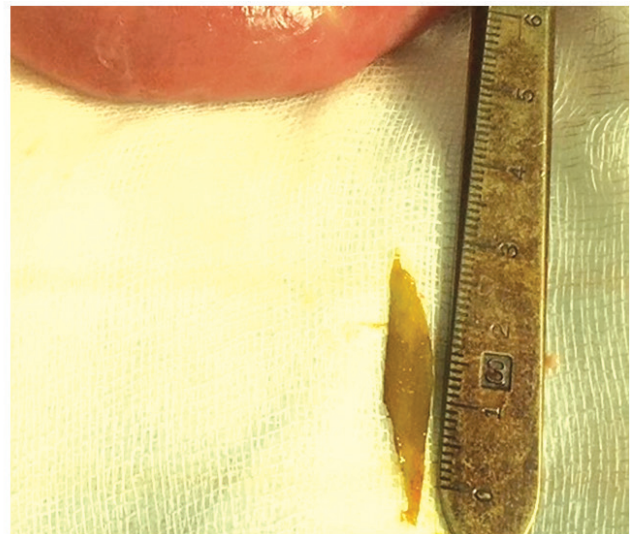
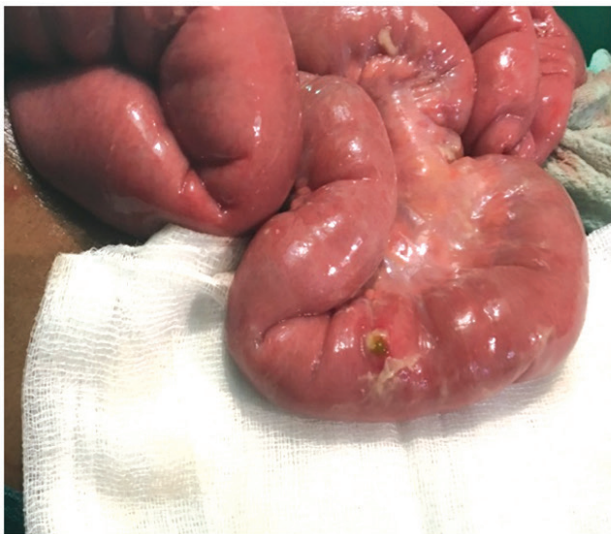Twenty years male was presented to the emergency department of Dhulikhel Hospital on 1st October, 2017. His initial complaints were related to progressive, severe abdominal pain in the left lumbar and epigastrium for the past 2 days. There was no history of trauma. We related the onset of his pain with dashain (major religious festival of Nepal). The patient was anxious but cooperative and the general condition was good. Patient was passing stool and flatus till the day of presentation and was afebrile. The patient had generalized abdominal tenderness and rebound tenderness. Bowel sound was hypoactive. Hernia orifices were intact. Renal angles were non-tender on both sides. Digital rectal examination was normal. Investigations revealed, his total leucocyte Count was 16400/mm<sup>3</sup> with neutrophil 87%, other

blood parameters were normal. Urinalysis revealed RBC (Red Blood Cells) was 23-26/high power field. Abdominal X-ray showed frank “Gas under diaphragm” under both domes. The bone was not visible due to gassy abdomen. Bowel loops were dilated. Sonographic evaluation of the abdomen revealed minimal ascites.

On the basis of above mentioned tests and consultation, we prepared the patient for surgery with our provisional diagnosis of Hollow viscous perforation. We thought the patient had some form of peptic ulcer perforation. We planned laparoscopic Modified Graham’s patch repair and the written as well as verbal consent was taken from the patient including his family. As we performed diagnostic laparoscopy, there was approx one liter bilious fluid in the right iliac fossa and Sub-hepatic space. Bowel loops were dilated. Omentum was oriented towards right iliac fossa. Even after pushing air from orogastric tube, we couldn’t find the perforation. So, we switched to open procedure. After midline incision, we examined

the stomach and parts of duodenum but perforation was nowhere to be found. We palpated entire small bowel for perforation. As I neared the appendix region, a sharp object pricked my finger. Upon close observation, we saw a tiny pin-point perforation in the distal ileum (approximately 20cm proximal to ileo-caecal junction). The sharp object was a small piece of bone. The bone’s body was more or less flat but had pointed-ends. The pointed-ends had perforated the ileum. We extended the perforation to remove the bone, margins refreshed and closed primarily. Thorough washing done and a drain pipe was kept in pelvis. Upon inquiring the patient about his meat intake, he acknowledged a retrospective history of mutton along with its bone.

The patient gradually improved, pipe drain was removed on the 3rd Postoperative day, and patient was discharged on the 5th postoperative day with the advice of a normal diet. Follow up on the 10th postoperative day was non-significant, and the sutures were removed.



**Figure 1:** Intra-operative finding of perforation in the ileum (left), and foreign body and measuring scale (right)

## DISCUSSION

Accidental swallowing of foreign body is a common complaint in clinical practice. It is more frequent complaint among children but the clinical diagnosis in that particular age group is not that difficult. Most of the foreign bodies ingested are expelled via stool without causing any harm. The perforation of

small bowel (commonly ileum) due to ingestions is estimated to be about 1%<sup>2</sup>. Common materials that cause perforation include: fish bones, chicken bones and toothpicks<sup>3</sup>. However, in people who play pens in their mouth, nails, nail clippers, batteries and pegs may also be a cause of gastrointestinal perforation.

There are very few reported cases of gastrointestinal perforation due to foreign body. Some reports attribute perforation due to migrated biliary stents. Madrona et al. reported chicken bone as the most common cause of gastrointestinal perforation due to foreign bodies<sup>1</sup> while Chu et al. reported that fish bones are most common cause of perforation in Hong Kong<sup>5</sup>. The difference in the causes might be due the preference and availability of food choices in the specified area.

The perforation from such foreign bodies tend to occur at sites of angulation like ileo-caecal, recto-sigmoid or the gastroduodenal junction, it can occur anywhere in the whole gastrointestinal tract<sup>6,7</sup>. Study by Goh et al. found the most common site of perforation due to ingested fish bone is at the terminal ileum (38.6%)<sup>8</sup>. In our case, the perforation was found approximately 20 cm proximal to ileo-caecal junction. Though many people have silent passage of foreign bodies, patients often may suffered with bowel perforation, abdominal abscess, internal fistulas, inflammatory mass, omental pseudotumor, intestinal obstruction or bleeding<sup>9</sup>. Even with a detailed history, diagnosis is difficult as the patient often don't recall accounts of meat ingestion nor is it possible for the clinicians to readily suspect all circumstances.

Detection by ultrasound is more important for radiolucent objects as they can't be visualized on radiographic imaging. X-ray of abdomen can detect obstructions; perforations and can detect the foreign bodies which are radio-opaque. Computed Tomography of abdomen can be a better tool to exclude other diagnosis as well as to detect foreign body<sup>10</sup>. However, in suspected DU perforation cases these modalities of investigation are not thought of. Therefore in our case, we proceeded without CT abdomen as our provisional diagnosis was peptic ulcer perforation. As per standard protocol, we did laparotomy, removed the foreign body, closed the perforation, thoroughly washed the abdomen, and the patient improved.

## CONCLUSION

Foreign body as a cause of bowel perforation is a very rare case. Pre-operative diagnosis in such case is an ever challenging issue which warrants knowledge sharing for the benefit of medical community.

## REFERENCES

1. Madrona AP, Angel J, Hernández F, Prats C, Riquelme R, Paricio PP. Intestinal Perforation by Foreign Bodies. *Eur. J. Surg.* 2000;166(4):307–309.
2. Selivanov V, Sheldon GF, Cello JP, Crass R. Management of foreign body ingestion. *Ann. Surg.* 1984;199(2):187–91.
3. Abdullayev R, Aslan M. Ileal perforation by an odd foreign object. *Turkish J. Surg.*, 2015;31(2):107–109.
4. Pulat H, Karakose O, Benzin MF, Benzin S, Cetin R. Small bowel perforation due to fish bone: A case report. *Turkish J. Emerg. Med.* 2015;15(3):136–138.
5. Nicolodi GC, Trippia CR, Caboclo MF, de Castro FG, Miller WP, de Lima RR et al., “Intestinal perforation by an ingested foreign body,” *Radiol. Bras.* 2016;49(5):295–299.
6. Maleki M, Evans WE. Foreign-body perforation of the intestinal tract. Report of 12 cases and review of the literature. *Arch. Surg.* 1970;101(4):475–7.
7. Goh BK, Chow PK, Quah HM, Ong HS, Eu KW, Ooi LL, Wong WK. Perforation of the Gastrointestinal Tract Secondary to Ingestion of Foreign Bodies. *World J. Surg.* 2006;30(3):372–377.
8. Rodríguez-Hermosa JI, Codina-Cazador A, Sirvent JM, Martín A, Gironès J, Garsot E. Surgically treated perforations of the gastrointestinal tract caused by ingested foreign bodies. *Colorectal disease.* 2008 Sep;10(7):701-7.
9. Coulier B. Diagnostic ultrasonography of perforating foreign bodies of the digestive tract. *J. Belge Radiol.* 1997;80(1):1–5.

### How to cite this article?

Bhatta G, Malla B, Rajbhandari N. A Rare Case Report on Ileal Perforation due to Ingested Mutton Bone. *Journal of Karnali Academy of Health Sciences.* 2019;2(1):70-72

Conflict of Interest: None Source of Support: None